

A Mouse Model for Vitiligo*

Aaron B. Lerner, M.D., Ph.D., Tetsuo Shiohara, M.D., † Raymond E. Boissy, Ph.D.,
Kirsten A. Jacobson, B.A., M. Lynn Lamoreux, Ph.D., ‡ and Gisela E. Moellmann, Ph.D.

Department of Dermatology, Yale University School of Medicine, New Haven, Connecticut, U.S.A.

As the result of a long search for a depigmenting mouse that could serve as a model for the study of vitiligo, we have located a strain that arose from the C57BL/6J. Its provisional genetic designation is C57BL/6J *Ler-vit/vit*. This vitiligo mouse has congenital dorsal and ventral white spots (piebaldism) as well as progressive replacement of pigmented hairs by white hairs with each spontaneous molt or after plucking. The lack of pigment is due to the absence of melanocytes from the amelanotic hair follicles and epidermis. As in human beings and the Smyth chicken model, there is also diminution of ocular pigment.

Reciprocal skin transplants between C57BL/6J and vit-

iligo mice, and transplants into nude mice, suggest a programmed pigment cell death in the vitiligo mice. Like human beings with vitiligo, maximally depigmented vitiligo mice have a decreased contact sensitivity response in comparison to age-matched C57BL/6J controls. The resistance to injected B16 melanomas is lowered. Vitiligo mice show no signs of premature aging.

Already at this early stage in the study of this new animal model, there are findings that open a range of new approaches to the study and treatment of patients with vitiligo and melanomas. *J Invest Dermatol* 87:299-304, 1986

Rapid progress can be made in the understanding of a disorder that occurs in human beings when an experimental animal model is available for study. The history with regard to an animal model for vitiligo does not go back far. Until about 15 years ago most physicians considered vitiligo to be a disorder exclusive to human beings. From our own search we now realize that probably all vertebrates with melanin pigmentation can develop vitiligo. There are examples of the typical pigment loss around eyes, nostrils, mouth, and footpads in dogs, cats, horses, pigs, and elephants [1-3]. Progressive depigmentation also occurs in chickens [4-6] and fish. In human beings, vitiligo is a disorder that is important medically for a number of reasons: the emotional impact of this cosmetically disfiguring condition on patients and their families is severe [7]; we must explain the high incidence of depigmentation in patients with a variety of autoimmune disorders [1]; vitiligo may lead to impaired vision [8]; and the incidence of vitiligo is increased in patients with melanomas [9].

The loss of skin color in vitiligo is due to the disappearance of epidermal pigment cells [10]. The precise mechanism of this elimination of melanocytes is not known, but immunologic factors may play a role with genetic, neural, and chemical factors contributing. It is likely that knowledge regarding the mechanism of melanocyte destruction in vitiligo can be used in treating patients with melanomas. To understand pigment cell loss in relation to autoimmunity and proliferation of malignant melanocytes we need a laboratory animal in which vitiligo and melanomas can be combined.

There are excellent experimental models for melanomas in mice (Cloudman S91, B16, and Harding Passey), hamsters (Fortner, Greene, and Bomirsky), and fish (Anders). Melanomas from these animals have been used extensively and productively for the study of the genetics and molecular biology of melanoma cells, melanin biosynthesis, and mechanisms of cellular responses to hormones [11,12]. The mouse and hamster melanomas arose spontaneously and have been propagated by transfer, first in animals and later in cell culture. Animals with a combination of melanomas and integumental pigment loss include Arabian, Lippinzer, and other gray horses [3,13] as well as the Sinclair [14] and Duroc[§] pigs. These large animals are impracticable for the laboratory studies that need to be done.

The best studied experimental model for vitiligo is the Smyth chicken [4-6]. Beginning 12 years ago J. Robert Symth and his associates at the University of Massachusetts, Amherst, established a line of chicken by selectively breeding birds for their ability to depigment progressively. Associated with the amelanosis are blindness and thyroiditis and a hypersensitivity to immunologic challenge. Bursectomy delays and injection of Cyclosporin A blocks the amelanosis [15,16]. Already prior to the onset of depigmentation there are fine-structural and enzymic abnormalities that suggest a defect inherent to melanocytes. Also, in comparison with control chicken melanocytes, the melanocytes cultured from the neural crests of Smyth chicken embryos pro-

Manuscript received April 23, 1985; accepted for publication February 20, 1986.

Supported in part by United States Public Health Service grant 5 PO1 AM25252 and a Lita Annenberg Hazen research fellowship presented to ABL for support of TS.

*Abstracts of work pertaining to this communication have appeared in *J Invest Dermatol* 84, April 1985, and/or *Clin Res* 33, April 1985: Lerner AB, Shiohara T, Boissy RE, Jacobson KA: Growth and metastasis of B16 melanomas in C57BL/6J-*V_i/V_i* normal and *vi/vi* mutant mice. Boissy RE, Moellmann GE, Lerner AB: Ocular pigment cell pathology in the early graying C57BL/6J-*vi/vi* mouse model for vitiligo.

†Permanent address: Department of Dermatology, Kyorin University School of Medicine, 6-20-2 Shinkawa, Mitaka Tokyo 181, Japan.

‡Address: Biology Department, Texas A & M University, College Station, Texas 77843.

Reprint requests to: Aaron B. Lerner, M.D., Department of Dermatology, LCI 500, P.O. Box 3333, 333 Cedar Street, New Haven, Connecticut 06510.

Abbreviations:

DNCB: dinitrochlorobenzene

DNFB: dinitrofluorobenzene

FCS: fetal calf serum

[§]Hordinsky MK, Ruth G, Cutler B, Savino D, King R, Goltz R: Tumor regression and depigmentation: simultaneous occurrence in Duroc Swine with cutaneous melanocytic tumors (personal communication to ABL).

liferate poorly and develop large, pigmented autophagosomes which are similar to those in moribund Smyth feather melanocytes [6] or in some of the melanocytes at the depigmenting borders of white spots in patients with vitiligo. It is not known whether in the Smyth chicken the abnormally functioning melanocytes evoke a response from a normal immune system, which then becomes unbalanced causing the birds to become hypersensitive, or whether both the melanogenic and the immune systems are defective a priori. Thus, there is a useful experimental model for vitiligo in a chicken, but no chicken has been found with a melanoma.

To study the parameters involved in the destruction of benign and malignant melanocytes, and to be able to develop an effective immunologic treatment for patients with melanomas, we need a mouse that is predisposed to getting vitiligo and can be used in conjunction with the mouse models for melanomas. For more than 10 years we have been searching for a murine strain with vitiligo. We have checked throughout the world with individual investigators and with directors of laboratories that breed mice. We found 6 depigmenting strains—4 from the USA, 1 from Great Britain, and 1 from Australia.

One of these strains (Fig 1), provided by Dr. Elizabeth S. Russell at The Jackson Laboratory, Bar Harbor, Maine, may enable us to develop the model we need. The depigmentation mutation occurred spontaneously in the C57BL/6J(B6) strain and is inherited as a simple recessive trait. The mouse, which we named C57BL/6J *Ler-vit/vit*, || hereafter referred to as the *vit/vit* or vitiligo mouse, shows congenital white spotting on its back and abdomen (Fig 1A) as well as progressive graying of the pigmented areas with each spontaneous hair molt (Figs 1B, 2) or after plucking (Figs 1C, 2).

MATERIALS AND METHODS

Animals C57BL/6J (B6) and vitiligo mice were purchased from The Jackson Laboratory, Bar Harbor, Maine approximately 6 years ago and propagated in our own animal care facilities.

Hair Counts Hairs were plucked from the dorsum of each mouse and taped to microscope slides. With the aid of a transmission photomicroscope, at a magnification of 400 \times , the hairs were counted and categorized as pigmented or amelanotic.

Skin Transplants Four-week-old, sex-matched *vit/vit*, B6, or nude mice were anesthetized with 5% sodium pentobarbital, and 3- to 5-mm grafts were taken from the dorsal and ventral regions, placed in Hanks' balanced salt solution with penicillin/streptomycin, and cleaned of adipose tissue. Multiple grafts (generally 4, from a total of more than 200) were transplanted onto prepared recipient hosts, in these permutations: B6 onto *vit/vit* or nude (on BALB/c or B57BL/6 background); B6 onto B6; *vit/vit* pigmented onto *vit/vit* piebald and vice versa; *vit/vit* pigmented onto B6 or nude; *vit/vit* piebald onto B6; nude onto nude. The host mice were bandaged for 10 days, after which time the bandages were removed and the coat color of the grafts was observed at weekly intervals, some up to a total of 25 weeks posttransplantation.

Injection of Cultured Melanoma Cells B16 murine melanoma cells were maintained in F-10 medium supplemented with 7% Nu-Serum and 3% fetal calf serum (FCS). They were harvested with EDTA, rinsed, and injected as a suspension in F-10 medium. In one experiment, 16-week-old female *vit/vit* and B6 mice (n = 9 each) were injected with 5 \times 10⁶ melanoma cells into the dorsal surface of the right ear and 1 \times 10⁶ cells into the dorsal surface of the left ear. In another experiment, 12-week-old female *vit/vit* and B6 mice (n = 5 each) were injected with 2 \times 10⁶ cells into the dorsal surface of both ears. Tumor growth was assessed in terms of tumor diameter:

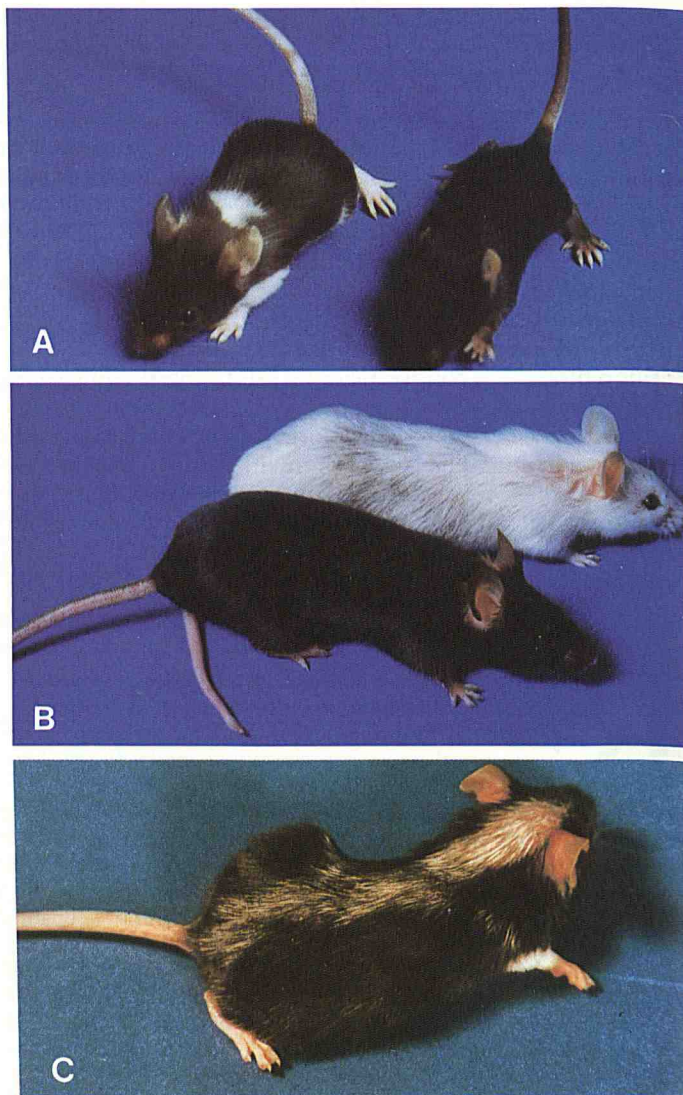


Figure 1. Photographs of C57BL/6J-*Vit/Vit* normal (B6) and *vit/vit* mutant (vitiligo) mice. **A**, Age 3 weeks. *Left*, *vit/vit*; *right*, B6. In addition to a piebald abdomen this *vit/vit* mouse has a dorsal piebald spot at the nape. The basic hair color at birth of the mutant mice is lighter than that of the B6 control mice. **B**, At 2 years of age this vitiligo mouse has lost almost all of its integumental pigment. Age of B6 mouse, 1 year. **C**, A vitiligo mouse (age 7 months), 3 weeks after the hairs were plucked from the middorsal region. In this animal, the proportion of amelanotic hairs in the regrowth is highest in the cranial region.

Experimental metastases were determined by injecting 4 \times 10⁵ B16 melanoma cells into the tail veins of 16-week-old female *vit/vit* and B6 mice. At 14 days postinjection, the mice were sacrificed, the lungs harvested, and pulmonary surface nodules counted with the aid of a dissecting microscope.

Testing for Contact Sensitivity Response Age-matched mice were sensitized by epicutaneous application of dinitrofluorobenzene (DNFB), 0.5% in a mixture of olive oil in acetone 1:4, on shaved back or abdomen. Five days later, 0.2% DNFB was applied to the ears and ear swelling was measured 24 h later.

RESULTS

Phenotype The natural graying of the pigmented areas can be categorized into 2 forms: congenital and acquired. At initial hair growth, the hairs are uniformly lighter than their B6 counterparts (Fig 1A). The subsequent, progressive graying is due to a gradual replacement of pigmented hairs by amelanotic, completely white

|| Provisional designation, to be announced in *Mouse News Letter* February 1986.

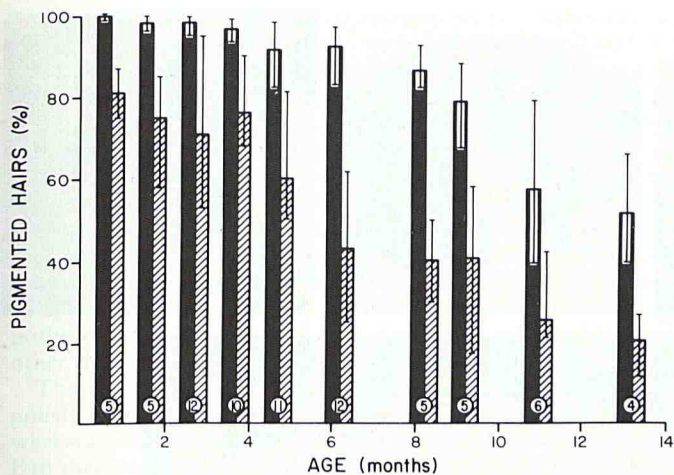


Figure 2. Progressive loss of pigmentation in the pelage of vitiligo mice before and 2 weeks after plucking of dorsal hairs. Telogen hairs (solid bars) and subsequent 2-week-old regenerating, anagen hairs (hatched bars). Each bar represents approximately 300 hairs. The encircled numerals denote the number of animals in each group. The line bars indicate the range of percentages within the respective batches of hair.

hairs during successive molts (Fig 2). During the period of natural graying, dopa-reactive melanocytes disappear from the hair follicles and epidermis [17], as seen by light microscopy. Electron microscopy of ear epidermis during aging [17] and of amelanotic hair bulbs after plucking (Boissy, to be published) has confirmed the absence of pigment cells. Vitiligo mice have no outward signs of premature aging nor do they have a shortened life span.

The pigmented portions of newborn vitiligo mice have a uniformly dark gray color that differs little from animal to animal, but the rate of replacement of pigmented by amelanotic hairs differs among individuals (Fig 2). Plucking hairs from vitiligo mice promotes the regrowth of amelanotic hairs in the plucked areas (Fig 1C), and this induced graying shows a wider range of variation among animals of the same age than occurs during the normal course of graying (Fig 2).

As in humans with vitiligo, there is irregularity of ocular pigmentation (Boissy, to be published): in adult gray mice, in the posterior portion of the eye cup, irregular amelanotic patches are apparent macroscopically with backlighting of the eye. Histologically, these patches are largely devoid of melanin. In the pigmented areas most of the melanocytes are histologically normal.

In newborn vitiligo mice, in contrast to B6 mice, there is as yet no uveal pigment. Some pigment appears in the iris and ciliary body by day 4 and in the choroid by week 3. Accompanying the delayed onset of pigmentation is the appearance of conspicuous, spherical, amelanotic cells, first along the anterior surface of the iris, later also in the ciliary body and stroma. These cells become numerous in the ensuing weeks and gradually acquire large melanophagosomes. Whether or not the spherical cells contain mel-

anin, they have numerous surface ruffles and are larger than melanocytes. They probably are macrophages.

No tests of visual acuity have been performed on vitiligo mice. In contrast to the Smyth chicken, the eyes of vitiligo mice remain dark to the unaided observer, even in maximally depigmented animals.

Inheritance The vitiligo mouse is the only murine example known in which congenital spotting (piebaldism) and vitiligo occur together. In white-spotted, early graying horses no correlation has been found between these 2 traits [13]. We have confirmed that the white spotting and the early graying phenotypes in the vitiligo mouse are inherited together as a recessive trait (Table I). Nevertheless, there are variations in the expression of both traits. White spotting ranges from approximately 8–46% of the animals' total pelage. Selective pressure on the extent of piebaldism did not result in segregation of that trait nor did it influence the rate of the associated vitiligo. It is possible that the white spotting is not classically recessive: outcrossing and backcrossing of the *vit/vit* line to the B6 line resulted in white abdominal spots ranging in diameter from $\frac{1}{16}$ "– $\frac{1}{4}$ " in approximately 50% of the progeny (Table I).

Reciprocal Skin Transplants Between B6 Normal and *vit/vit* Mice, and Transplants to Athymic (Nude) Mice Sera from patients with vitiligo contain antibodies directed against melanocytes [18,19]. The question as to whether these antibodies contribute in the killing of pigment cells remains to be answered. Patients with melanomas who develop vitiligo have an extended life span in comparison with those who do not [20]. If an immune response directed against melanocytes is responsible for the destruction of pigment cells in patients with vitiligo or with vitiligo and melanoma, and in the *vit/vit* mice, one might expect that the hair color of B6 skin grafted onto the histocompatible vitiligo mice during the period of their progressive depigmentation would lighten. This is not the case, but rather the opposite is true. Pieces of skin were taken from the back or abdomen of donor mice and grafted onto the back or abdomen of sex-matched recipient mice [21]. When dorsal or ventral B6 skin was transplanted to similar sites on B6 mice, young graying vitiligo mice, mature gray vitiligo mice, or nude mice, the hair color of the grafts remained black for as long as 16 weeks (Fig 3A,D). When *vit/vit* skin from mature gray or young early graying mice was grafted onto the back or abdomen of B6 mice or nude mice, all hair in the grafts turned white (Fig 3A,D). When *vit/vit* skin from early graying mice was grafted onto the back or abdomen of other early graying mice, some of the grafts retained their original color for as long as 13 weeks (Fig 3C) whereas others turned white.

These findings show that, contrary to our original assumption, vitiligo mice do not destroy histocompatible control pigment cells and may, in fact, provide a supportive environment for the limited survival of their own melanocytes. That the loss of *vit/vit* melanocytes in B6 hosts is not necessarily due to an immune response against them is indicated by the equally effective whitening of the *vit/vit* grafts on the immunologically compromised, nude mice. Barring the remote possibility of local transfer of long-

Table I. Inheritance of Graying and Piebaldism in Vitiligo Mice

Parents		Progeny			Number of Mice
		% Graying	% Black	% Black with White Abdominal Spot (WAS)	
<i>Outcross to C57BL/6j</i>					
<i>vit/vit</i> × C57BL/6j	F ₁	0	58	42	52
F ₁ (WAS) × F ₁ (no WAS)	F ₂	26	48	26	65
		[1	: 2	: 1]	
<i>F₂ Backcross to C57BL/6j</i>					
F ₂ Black (WAS) × C57BL/6j		0	94	6	18
F ₂ Black (no WAS) × C57BL/6j		0	40	60	5

Figure 3. Reciprocal skin transplants between B6 and vitiligo mice and transplants onto nude mice. A, B6 (arrow) and *vit/vit* pigmented (arrowhead) onto B6 (16 weeks). B, B6 onto *vit/vit* (14 weeks). C, *vit/vit* pigmented onto *vit/vit* (14 weeks). D, Pigmented *vit/vit* (black arrows), B6 (black arrowhead), and nude (white arrowhead) onto BALB/c nude (> 16 weeks).

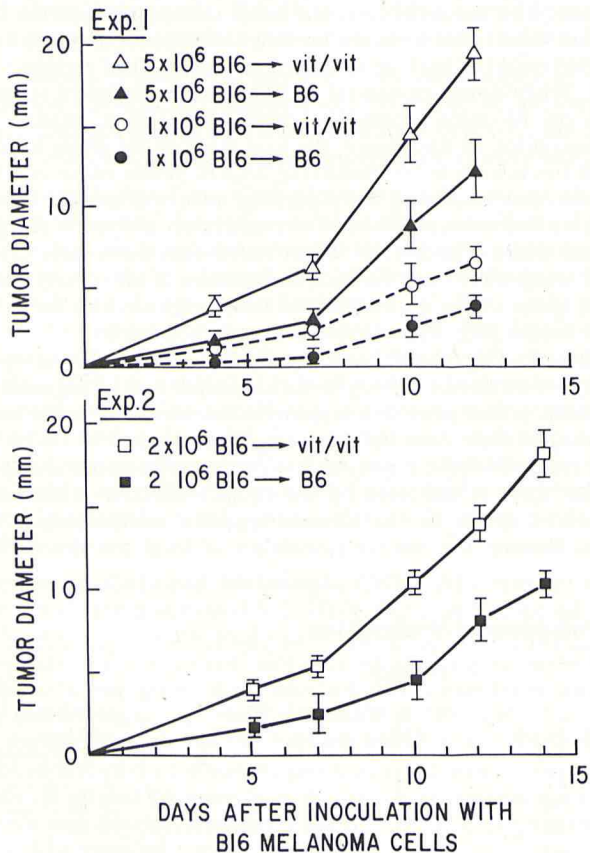
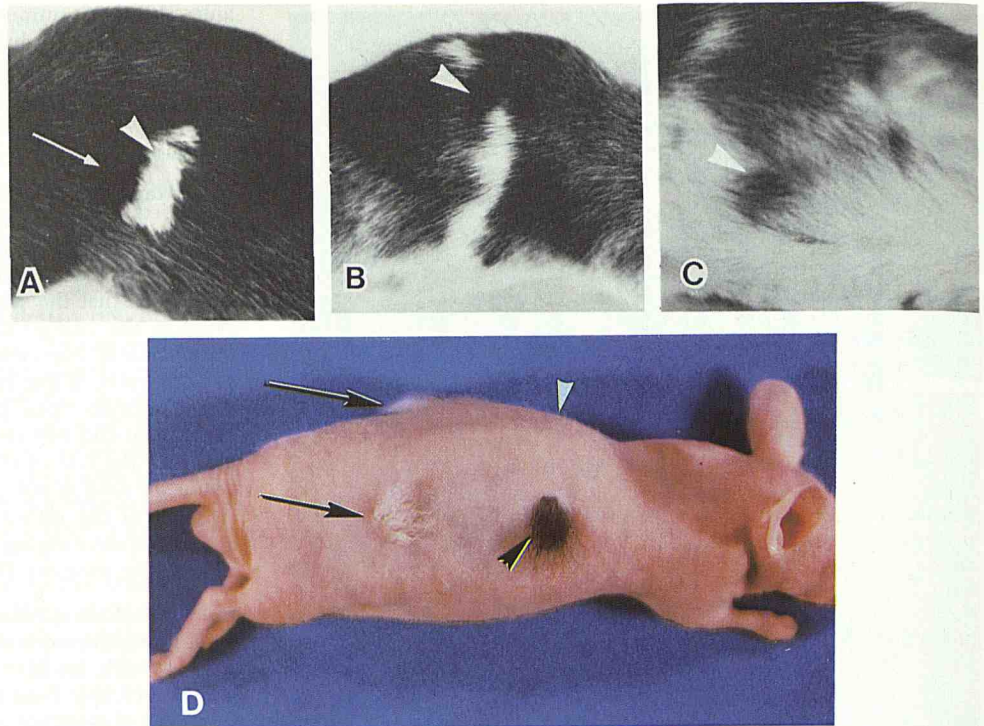


Figure 4. *Vit/vit* and B16 melanomas (I). Comparative size of experimental tumors. The *vit/vit* mice were in the period of progressive depigmentation.

acting, graft-indigenous immune factors during grafting, these findings make it appear unlikely that vitiligo in the *vit/vit* mouse is an autoimmune disease in the common sense of the concept. Rather, these findings point to the possibility of a primary melanocytic dysfunction in the etiology of the acquired amelanosis. This idea is supported by the documented dysfunction of melanocytes in the Smyth chicken [6] and by the clinical impression that patients with vitiligo respond more favorably to chemical depigmenting agents than do individuals who do not have vitiligo. The data also go along with the paucity of cellular infiltrates noted in the borders of advancing lesions in patients with common vitiligo [22] and suggest that the melanocyte-binding antibodies found in such patients may be a consequence rather than the cause of cell injury.

Vitiligo Mice and Melanomas We have suggested on the basis of clinical and epidemiologic findings in families with both vitiligo

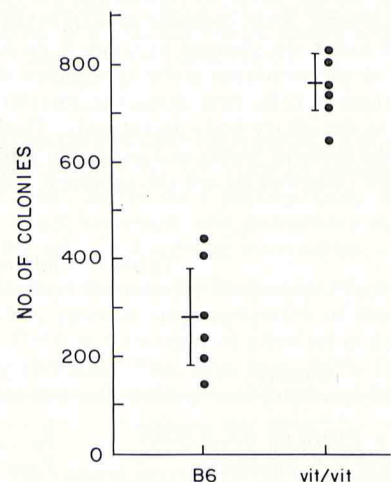


Figure 5. *Vit/vit* mice and B16 melanomas (II). Comparative number of experimental metastases. Again, the vitiligo mice were in the period of progressive depigmentation.

and melanomas that the melanocytes of people with vitiligo or with a genetic background for vitiligo may be predisposed to becoming transformed to melanomas [20]. Another hypothesis would be that melanocytes, once transformed, find a favorable growth environment in the vitiligo patient, but, originating from inherently defective cells, the vitiligo melanomas grow less rapidly. If these hypotheses are correct and held to be the case with the vitiligo mouse, one would expect the incidence of spontaneous melanomas and the growth rate of exogenously administered B16 melanomas to be higher in vitiligo mice than in the B6 controls. Because mice in general are not known to have a high incidence of spontaneous melanomas, we decided to test the second hypothesis, knowing full well that melanoma cells derived from other than *vit/vit* mice may tell only half the story.

The growth rates and the incidence of metastases of exogenously administered melanomas were determined in 12- to 16-week-old B6 and in *vit/vit* mice. After local injection of cultured B16 melanoma cells, tumors grew significantly faster in the depigmenting *vit/vit* mice than in age- and sex-matched B6 controls (Fig 4). Also, the vitiligo mice died earlier than relevant controls. Metastases were determined by injecting melanoma cells into the tail vein and counting pulmonary surface nodules. The number of nodules in the vitiligo mice was more than double that in the B6 mice (Fig 5).

When similar experiments were performed with younger mice, 6-7 weeks of age, before the time of onset of depigmentation in the *vit/vit* mice, the differences between *vit/vit* and control B6 mice were less pronounced. These results indicate that during the period of progressive depigmentation vitiligo mice favor, or are impaired in their ability to restrict, the growth of B16 melanoma cells at the dosage administered.

Contact Sensitivity in B6 Normal and *vit/vit* Mice Contact sensitivity tests with dinitrochlorobenzene (DNFB) on patients with vitiligo revealed that the response to challenge was diminished in the depigmented patches of skin regardless of whether sensitization was performed on pigmented or depigmented areas [23]. Because we know that the pigmented skin of vitiligo patients cannot be considered normal and be used as a control [22], we have extended these experiments and have found that patients with vitiligo in general have a lower contact sensitivity response to DNFB than individuals who do not have vitiligo (Huberman, Jacobson and Lerner, to be published).

Sex-matched B6 and *vit/vit* mice, before the onset of depigmentation in the vitiligo mice, were sensitized with DNFB and challenged as outlined in *Materials and Methods*. B6 and *vit/vit* mice responded equally to the challenge dose regardless of the sensitization site (Table II). This experiment shows that the con-

genital lack of melanocytes in the piebald abdominal skin of *vit/vit* mice does not affect the bulk antigen-presenting ability of the epidermis or the elicitation of the responses to DNFB contact sensitization.

On the other hand, maximally depigmented vitiligo mice at 35 weeks of age exhibited a decreased contact sensitivity response as compared with their B6 controls regardless of the site of sensitization (Table II). These results provide a definite indication for an immune dysfunction in the older vitiligo mice.

COMMENT

From the results of experiments presented in this paper, it is likely that we have a mouse model for vitiligo. Having 2 animal models, the chicken and the mouse, plus being able to grow nonmalignant pigment cells in culture means that the basic tools are in hand to study the etiology of vitiligo as well as to understand the important relationship between vitiligo and melanomas.

We thank Dr. Akihiko Tamura for critical reading of the manuscript and Jack Schreiber for skillful secretarial assistance. We are indebted to Dr. Michael R. Lerner for suggesting the transplants into nude mice.

REFERENCES

- Lerner AB, Nordlund JJ: Vitiligo: what is it? Is it important? *JAMA* 239:1183-1187, 1978
- Lerner AB, Nordlund JJ: Vitiligo: the loss of pigment in skin, hair and eyes. *Jpn J Dermatol* 5:1-8, 1978
- Lerner AB, Cage GW: Melanoma in horses. *Yale J Biol Med* 46:646-649, 1973
- Smyth JR Jr, Boissy RE, Fite KV: The DAM chicken: a model for spontaneous postnatal cutaneous and ocular amelanosis. *J Hered* 72:150-156, 1981
- Boissy RE, Smyth JR Jr, Fite KV: Progressive cytological changes during the development of delayed feather amelanosis and associated eye defects in the DAM chicken line. A vitiligo model. *Am J Pathol* 111:197-212, 1983
- Boissy RE, Moellmann G, Trainer AA, Smyth JR Jr, Lerner AB: Delayed-amelanotic (DAM or Smyth) chicken: melanocyte dysfunction in vivo and in vitro. *J Invest Dermatol* 86:149-156, 1986
- Porter J, Beuf A, Nordlund JJ, Lerner AB: Personal response of patients to chronic skin disease. A study of patients with vitiligo. *Gen Hosp Psychiatry* 1:73-77, 1979
- Albert DM, Nordlund JJ, Lerner AB: Ocular abnormalities occurring with vitiligo. *Ophthalmology* 86:1145-1158, 1979
- Lerner AB: Melanoma and vitiligo, *Contemporary Issues in the Management of Melanomas*. Edited by L Nathanson. New York, Churchill-Livingstone, in press, 1986
- Mishima Y, Kawasaki H, Pincus H: Dendritic cell dynamics in progressive depigmentations. Distinctive cytokinetics of α -dendritic cells revealed by electron microscopy. *Arch Dermatol Forsch* 243:67-87, 1972
- Seiji M (ed): *Pigment Cell 1981*, Proceedings of the XI International Pigment Cell Conference, Sendai, Japan, 1980. Tokyo, Univ of Tokyo Press, 1981
- Bagnara J, Klaus SN, Paul E, Shartl M (eds): *Pigment Cell 1985*, Proceedings of the XII International Pigment Cell Conference, Giessen, Federal Republic of Germany. Tokyo, Univ of Tokyo Press, 1985
- Sponenberg DP, Beaver BV: *Horse Color*, College Station, Texas A & M University Press, 1983
- Millikan LE, Hook RR, Manning PJ: Gross and ultrastructural studies in a new melanoma model: the Sinclair swine. *Yale J Biol Med* 46:631-645, 1973
- Lamont SJ, Smyth JR Jr: Effect of bursectomy on development of a spontaneous postnatal amelanosis. *Clin Immunol Immunopathol* 21:407-411, 1981

Table II. Contact Sensitivity Response to DNFB in C57BL/6J (B6) Normal and *vit/vit* Mutant Mice

Sensitization Site	Age (weeks)	Increase in Ear Thickness (mm $\times 10^{-2}$)	
		B6	<i>vit/vit</i>
Back	9 ^a	17.4	17.7
	24 ^b	26.5	19.4
	35 ^c	15.3	6.4 ^d
Abdomen ^e	9 ^a	16.9	15.5
	24 ^b	23.0	16.6
	35 ^c	13.3	5.5 ^d

A total of 36 mice were sensitized with DNFB 0.5% on shaved back or abdomen. Five days later, 0.2% DNFB was applied to the ears and ear swelling was measured 24 h later.

^aBefore the onset of depigmentation in the vitiligo mice.

^bDuring the period of pigment loss.

^cAfter maximal depigmentation has occurred.

^d $p < 0.005$ between controls and mutants.

^ePiebald in the vitiligo mice.

16. Lamont SJ, Smyth JR Jr: Effect of cyclosporin A on delayed amelanosis (abstr). Midwest Autumn Immunol Conference Proceedings, Chicago, IL, 1983
17. Bell M, Rheins LA, Nordlund JJ: Cytologic alterations in the epidermis of the depigmenting C57BL vi/vi mouse. *J Cell Biol* 99:386a, 1984
18. Naughton GK, Eisinger M, Bystryk J-C: Detection of antibodies to melanocytes in vitiligo by specific immunoprecipitation. *J Invest Dermatol* 81:540-542, 1983
19. Moellmann GE, Krass P, Halaban R, Kuklinska E, Lerner AB: On the subject of serum antibodies to melanocytes in vitiligo (abstr). *J Invest Dermatol* 84:333, 1985
20. Lerner AB, Kirkwood JM: Vitiligo and melanomas: can genetically abnormal melanocytes result in both vitiligo and melanoma within a single family? *J Am Acad Dermatol* 11:696-701, 1984
21. Billingham RE, Silvers WK: *The Immunology of Transplantation*. Englewood, NJ, Prentice Hall, Inc, 1971
22. Moellmann G, Klein-Angerer S, Scollay DA, Nordlund JJ, Lerner AB: Extracellular granular material and degeneration of keratinocytes in the normally pigmented epidermis of patients with vitiligo. *J Invest Dermatol* 79:321-330, 1982
23. Uehara M, Miyauchi H, Tanaka S: Diminished contact sensitivity response in vitiliginous skin. *Arch Dermatol* 120:195-198, 1984

This document is a scanned copy of a printed document. No warranty is given about the accuracy of the copy. Users should refer to the original published version of the material.